



PATIENT

Udder Tort Robertson

PRESENTING CLINICAL SIGNS

History: Acute paraparesis. Differential BGs - 124 and 134 mg/dl. BP: 142mmHg. Assess prior to MRI. -Radiographs: Show cardiomegaly.

SPECIES

Feline

RADIOGRAPHIC FINDINGS *NOTE: Images submitted for supplemental cardiac information only.

Mild cardiomegaly with increased sternal contact. No obvious evidence of CHF.

BREED

DSH

ECHOCARDIOGRAM FINDINGS

2D, m-mode, color flow and doppler imaging is available. The left ventricular wall is normal in dimension. There is a mildly hyperechoic endocardium consistent with mild fibrosis. The endocardium also appears mildly remodeled. The papillary muscles are mildly hypertrophied and hyperechoic. The left atrium is normal in size. The right atrium is normal in size. The right ventricle appears normal. The mitral valve is normal in structure and mobility. No obvious valve regurgitation. Blood flow through both the LVOT and RVOT is normal in velocity. No pleural or pericardial effusion seen. No obvious cardiac tumors.

AGE

13 years

CARDIAC CHART

WEIGHT

NP

FELINE CARDIAC PARAMETERS	BODY WEIGHT (kg)	HR (BPM)	IVSd (cm) (Moise, Pipers)	LVIDd (cm) (Moise, Pipers)	LWVd (cm) (Moise, Pipers)	FS (%)	EF (%)
NORMAL PARAMETER	-----	150-240	0.35-0.55	<2 (mean 1.5)	3.5-0.55	35-67	80-100
PATIENT	NP	NM	0.49	1.2	0.47	50	92
FELINE CARDIAC PARAMETERS	LA/AO (Boon)	LA/AO HEART BASE (Swe) (Abbott)	LA 2D short axis Base view (cm) (Abbott)		LVOT VEL (m/s)	RVOT VEL (m/s)	E max (m/s)
NORMAL	<1.5	<1.3	<1.2		<1.6	<1.3	<0.9
PATIENT	NM	1.3	1.2		1.8	1.9	NM

INTERPRETED BY

Maggie Machen Lamy, DVM, DACVIM (Cardiology)

*Note: All measurements based upon multi-modal images and methods. An average value is reported.

Adapted from June Boon, Veterinary Echocardiography, 1998

Abbott J & MacLean H JVIM 2006;20: 111-119, Moise et al. Am J Vet Res 47:1476, 1986. Pipers et al. Am J Vet Res 40:882, 1979.

IMAGING PERFORMED BY

A. Nicastro, DVM

HOSPITAL NAME

Veterinary Specialty Care Blue Pearl Mt Pleasant

INTERPRETATION OF THE FINDINGS & FURTHER RECOMMENDATIONS

Overtly normal cardiac structure and function. The LV wall thickness is normal, and there is no evidence of elevated left atrial pressure or underlying pathology at this time. There is mild remodeling and fibrosis of the left ventricular wall, which is considered likely a normal age-related finding. Given these findings, no medications are indicated.

REFERRING VET

Dr. Graham

These findings would suggest a cardiogenic thrombus is highly unlikely. Other possibilities should be considered.

INVOICE

32283

No obvious structural cause for BNP elevation is seen here. A flaw of the BNP test is false positives, which may be the case; however, alternative causes for elevation should be considered, including decreased renal clearance, hypertension, etc. If no obvious cause is identified, reassessing this patient in 6-12 months is recommended to ensure early disease was not missed.

DATE

8/10/23



PATIENT

Udder Tort Robertson

SPECIES

Feline

BREED

DSH

SEX

Female Spayed

AGE

13 years

WEIGHT

NP

INTERPRETED BY

Maggie Machen Lamy,
DVM, DACVIM
(Cardiology)

IMAGING PERFORMED BY

A. Nicastro, DVM

HOSPITAL NAME

Veterinary Specialty
Care Blue Pearl Mt
Pleasant

REFERRING VET

Dr. Graham

INVOICE

32283

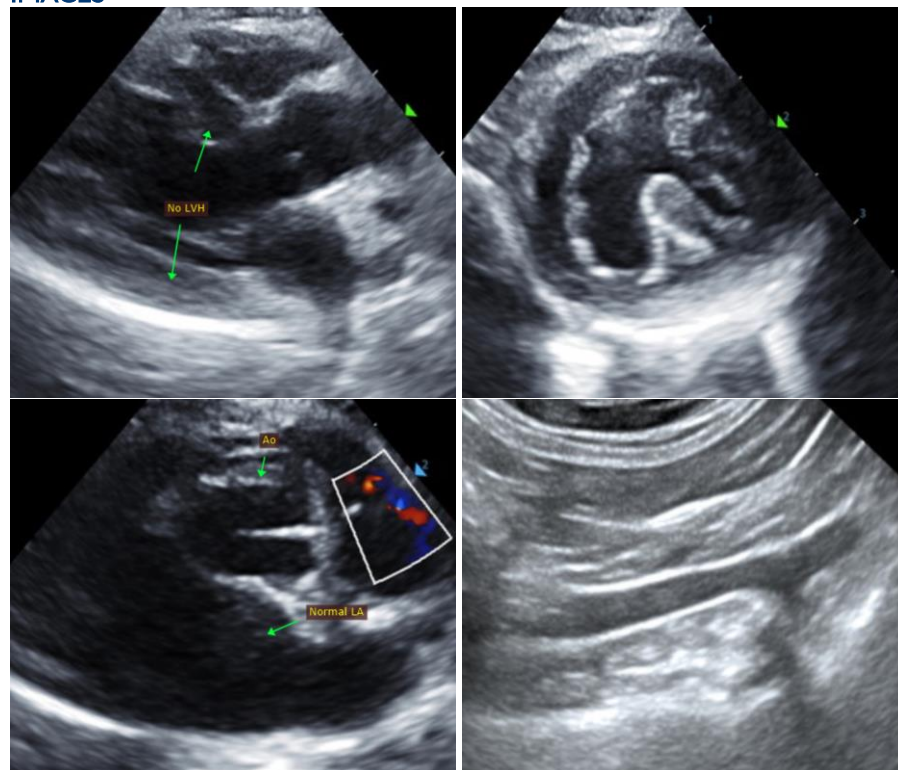
DATE

8/10/23

Anesthetic risk is considered mild. With remodeling and diastolic stiffening, there is an elevated risk for fluid overload in this patient and judicious IV fluid use is recommended. Heart rate stimulating drugs such as atropine, glycopyrrolate or ketamine should be avoided unless medically necessary. Risk for complication with steroid use typically follows LA dilation, which in this case is low. That being said, any cat can experience unexpected signs of intolerance and monitoring of RR/RE is advised particularly in the initiation phase.

Recommend recheck echocardiogram in 1 year to assess for any progressive issues.

IMAGES



The information and recommendations provided are based on the images presented by the referring veterinarian. No evaluation can be communicated regarding pathology that was not visible in the image/video clips provided.

Thank you for this referral. This report was generated using transcription software, and minor dictation errors may be present. If the clinical or image interpretation does not parallel your findings or if I can be of any further assistance, please contact me.

Maggie Machen Lamy, DVM
Diplomate of the American College of Veterinary Internal Medicine (Cardiology)
info@sonopath.com